



## Treatment of Striae Distensae Combined Enhanced Penetration Platelet-Rich Plasma and Ultrasound after Plasma Fractional Radiofrequency

Dong-Hye Suh, Sang-Jun Lee, Jong-Ho Lee, Hyun-Ju Kim, Min-Kyung Shin, Kye-Yong Song

10.3109/14764172.2012.738916

### Abstract

**Background:** Striae distensae (striae alba) is a challenging cosmetic problem for which various treatment modalities have been applied. However, the treatment of striae distensae has not been satisfactory. **Objectives:** This study was done to evaluate the effectiveness and the safety of enhanced penetration of platelet rich plasma with ultrasound after plasma fractional radiofrequency for the treatment of striae distensae.

**Subjects and Method:** Eighteen participants with striae distensae were treated with a Legato system (Alma Lasers, Israel) every three weeks for a total of three sessions. Thereafter, in order to enhance platelet-rich plasma penetration, ultrasound is applied. Clinical photographs were taken before first treatment and two months after the final treatment. Objective and subjective improvement scores were evaluated to demonstrate the efficacy. Abdominal skin biopsies were obtained from three individuals and histological changes analyzed by light microscopy.

**Results:** At two months after the last treatment, the average width of the widest striae had decreased from 0.75 mm to 0.27 mm. In the objective assessment, 71.9% of the participants reported "good" or "very good" overall improvement. In the subjective assessment, and 72.2% of the participants reported "very satisfied" or "extremely satisfied" with overall improvement. The only reported side effect was post-inflammatory hyperpigmentation (11.1%).

**Conclusions:** The plasma fractional radiofrequency and transepidermal delivery of platelet-rich plasma using ultrasound is useful in the treatment of striae distensae.

© 2012 Informa UK, Ltd. This provisional PDF corresponds to the article as it appeared upon acceptance. Fully formatted PDF and full text (HTML) versions will be made available soon.

DISCLAIMER: The ideas and opinions expressed in the journal's *Just Accepted* articles do not necessarily reflect those of Informa Healthcare (the Publisher), the Editors or the journal. The Publisher does not assume any responsibility for any injury and/or damage to persons or property arising from or related to any use of the material contained in these articles. The reader is advised to check the appropriate medical literature and the product information currently provided by the manufacturer of each drug to be administered to verify the dosages, the method and duration of administration, and contraindications. It is the responsibility of the treating physician or other health care professional, relying on his or her independent experience and knowledge of the patient, to determine drug dosages and the best treatment for the patient. *Just Accepted* articles have undergone full scientific review but none of the additional editorial preparation, such as copyediting, typesetting, and proofreading, as have articles published in the traditional manner. There may, therefore, be errors in *Just Accepted* articles that will be corrected in the final print and final online version of the article. Any use of the *Just Accepted* articles is subject to the express understanding that the papers have not yet gone through the full quality control process prior to publication.

# Treatment of Striae Distensae Combined Enhanced Penetration Platelet-Rich Plasma and Ultrasound after Plasma Fractional Radiofrequency

Dong-Hye Suh, Sang-Jun Lee, Jong-Ho Lee<sup>a</sup>, Hyun-Ju Kim, Min-Kyung Shin<sup>a</sup>, Kye-Yong Song<sup>b</sup>

Dermatology, Arumdaun Nara Dermatologic Clinic, Seoul, Korea, <sup>a</sup>Dermatology, Kyung-Hee University, Seoul, Korea, <sup>b</sup>Pathology, Chung-Ang University, Seoul, Korea

\*Correspondence to: Min Kyung Shin, M.D., Ph. D. Department of Dermatology, College of Medicine, Kyung Hee University, Seoul, Korea, Tel: +82-2-958-8300 Fax: +82-2-969-6538. E-mail: haddal@hanmail.net

## ABSTRACT

**Background:** Striae distensae (striae alba) is a challenging cosmetic problem for which various treatment modalities have been applied. However, the treatment of striae distensae has not been satisfactory.

**Objectives:** This study was done to evaluate the effectiveness and the safety of enhanced penetration of platelet rich plasma with ultrasound after plasma fractional radiofrequency for the treatment of striae distensae.

**Subjects and Method:** Eighteen participants with striae distensae were treated with a Legato system (Alma Lasers, Israel) every three weeks for a total of three sessions. Thereafter, in order to enhance platelet-rich plasma penetration, ultrasound is applied. Clinical photographs were taken before first treatment and two months after the final treatment. Objective and subjective improvement scores were evaluated to demonstrate the efficacy. Abdominal skin biopsies were obtained from three individuals and histological changes analyzed by light microscopy.

**Results:** At two months after the last treatment, the average width of the widest striae had decreased from 0.75 mm to 0.27 mm. In the objective assessment, 71.9% of the participants reported “good” or “very good” overall improvement. In the subjective assessment, and 72.2% of the participants reported “very satisfied” or “extremely satisfied” with overall improvement. The only reported side effect was post-inflammatory hyperpigmentation (11.1%).

**Conclusions:** The plasma fractional radiofrequency and transepidermal delivery of platelet-rich plasma using ultrasound is useful in the treatment of striae distensae.

Keywords: striae distensae, striae alba, RF, PRP, plasma fractional laser

## INTRODUCTION

Striae distensae is a very common cosmetic problem which develops during either puberty or pregnancy. Initially, striae appear as red to violaceous elevated lines (striae rubra). Over time, the lesions become atrophic, with the skin surface exhibiting a fine, white, wrinkled appearance (striae alba). Various modalities of treatment have been used to treat striae including topical retinoid therapy, chemical peels, ultrasound therapy, microdermabrasion, IPL, and near infrared lasers and have shown limited benefit to the patient. Pigmentary alteration is a major concern in many patients with darker skin types (V-VI).<sup>1</sup> It is difficult to obtain a successful outcome with striae alba.<sup>2</sup>

Legato is a combined laser system that increases effective ingredients using hammer treatment after plasma fractional radiofrequency. Platelet-rich plasma (PRP) is blood plasma with concentrated platelets. The concentrated platelets found in PRP contain large reservoirs of bioactive proteins, including growth factors that are vital to initiate and accelerate tissue repair and regeneration. Platelet-rich plasma contains autologous growth factors, especially epidermal growth factor, platelet-derived growth factor, transforming growth factor  $\beta$ , and vascular endothelial growth factor, that act synergistically with other growth factors.<sup>3</sup> Clinical effects of PRP include reduction of erythema and PIH after Ablative Fractional Carbon Dioxide Laser Resurfacing.<sup>4,5</sup>

The purpose of this study was to evaluate the clinical efficacy of plasma fractional ablative RF and enhanced PRP penetration using acoustic wave ultrasound for the treatment of striae distensae in Asian skin.

## SUBJECTS AND METHODS

Eighteen healthy female participants (average  $34.11 \pm 5.61$ , age range 27-39 year-old) from the Arumdaun Nara Dermatologic Clinic were enrolled in the study. All participants gave informed consent for treatment. Three individuals also gave informed consent for punch biopsy. The participants had Fitzpatrick skin types ranging from III to V. Three of 18 participants were skin type III, 12 were skin type IV, and three were skin type V. Participants showed clinical signs associated with striae distensae on the abdomen, buttock, and leg. All individuals presented with striae alba at least three years previous to study initiation.

Exclusion criteria were any treatment procedure for striae distensae including any type of laser modality within one year of study initiation, history of keloid scarring, connective tissue disease, diabetes, skin infection, vitamin A derivative use within two months of study initiation, pregnancy, use of immunosuppressive drugs, or any other disease which could affect the wound-healing process. Participants underwent three every-other-week treatment sessions with the Legato system (Alma Lasers Ltd. Israel).

Clinical photographs were taken using identical camera settings for high-resolution digital photographs (Canon, Tokyo, Japan) at baseline and two months after the final treatment. The width of the widest striae in each individual was measured at the baseline and two months after the final treatment. Clinical improvement was evaluated by two blinded dermatologists by comparing

photographs. The criteria for evaluations using a quartile grading scale were as follows: 0=no improvement, 1=mild (percent improvement, <25%), 2 =moderate (percent improvement, 25-49%), 3=good (percent improvement, 50-74%), and 4=excellent (percent improvement, >75%). In addition, a participant satisfaction score was rated using the following scale: 0=not satisfied, 1=slightly satisfied, 2=satisfied, 3=very satisfied, and 4= extremely satisfied. Biopsies were obtained from three individuals before the first treatment and two months after the final treatment. Biopsy specimens were fixed in 10% neutral formalin and embedded in paraffin. Each section was stained with hematoxylin and eosin (H&E) and Victoria blue (for elastic fiber analysis).

Images of each section were taken at magnification X200 with a 12.5 megapixel digital camera (DP70; Olympus Optical Co., Tokyo, Japan) connected to a light microscope (BX40; Olympus Optical Co.). The images were analyzed by MetaMorph (Molecular Devices, Sunnyvale, CA, USA).

#### ***Device and treatment protocol***

The Legato system is comprised of two distinct therapeutic handpieces: 1) plasma fractional ablative RF ("RF Pixel") and 2) acoustic wave pressure ultrasound ("IMPACT"). The RF Pixel is designed to produce a matrix of tiny wounds surrounded by a larger area of undamaged skin. The RF Pixel rolling tip handpiece delivers a matrix of RF energy to the skin ranging from 132 to 242-pixel spots per cm when the tip is rolled over the skin. The fractioned RF energy stimulates micro-plasma sparks between the skin surface and the RF electrode. After disinfection, a topical anesthetic (lidocaine 2.5% and prilocaine 2.5%) was applied for 60 minutes. Skin perforation with the RF Pixel was carried out using a 10-mm-wide rolling drum (six cogs) equipped with 50 electrodes at each cog circumference. RF Pixel skin coverage was sequentially performed over the affected areas for a total of two passes: a complete pass was considered a horizontal followed by a vertical pass. The RF Pixel handpiece was set at a power between 40-45 W. These micro-plasma sparks produced micro-channels having a depth and diameter ranging from 100 to 150  $\mu\text{m}$  and 80 to 120  $\mu\text{m}$ , respectively.

#### ***Platelet-rich plasma***

Platelet-rich plasma is obtained by the following method. First, 12 mL of autologous whole blood is collected into tubes containing acid-citrate-dextrose and centrifuged at 1,200 g for 15 minutes in order to obtain PRP at the top of the tube. Then, the PRP is further centrifuged at 1,800 g for 10 minutes to obtain a platelet concentrate with a platelet count 4.5 times higher than baseline and a platelet-poor plasma. The platelet-poor plasma is partly removed and used to resuspend the platelets. The purpose of the IMPACT handpiece's designed sonotrode is the organization of sufficient acoustic pressure, which enhances transport of the delivered drugs/substance to the area of previously perforated the skin. The treatment settings of the acoustic pressure ultrasound handpiece were 50% of the ultrasound energy output and 50 Hz for the ultrasound sonotrode vibration rate.

## RESULTS

At two months after the last treatment, the average width of the widest striae decreased from 0.75 mm to 0.27 mm.

In the objective assessment, two blinded reviewers rated 'excellent' results (75-100% improvement) in six of 18 (33.0%) participants, 'very good' (50-74% improvement) in seven (38.9%), 'good' (25-49% improvement) in four (22.4%), and 'mild' (1-24% improvement) in one (5.6%).

In the subjective assessment, 72.2% of the participants reported "good" or "very good" overall improvement.

The only reported side effect was post-inflammatory hyperpigmentation, which improved in four weeks, in two individuals (11.1%).

### *Histopathologic analysis*

Three participants were biopsied using a 2 mm handheld punch. The excised skin was fixed in 10% neutral formalin and embedded in paraffin. Hematoxylin and eosin (H&E) stains of the baseline striae showed unremarkable epidermal changes as expected and loosening of collagen density by H&E stain in both papillary and reticular dermis accompanying the decrease amount of elastic fibers by Victoria Blue stain (Fig. 1, 2). Post-treatment biopsy specimens showed the significant increase of both collagen and elastic fibers in papillary and reticular dermis, accompanying increase of subepidermal collagen density, also (Fig. 1, 2).

## DISCUSSION

Striae distensae are dermal scars with linear atrophic depression. Several treatments have been proposed, yet no consistent treatment modality is available. The first reliable method of treatment involved using tretinoin. In the late stage of SD, after which the scarring process is complete, effective treatment is more difficult. Of the many modalities used to ameliorate and improve stretch marks, lasers have recently become a popular therapeutic alternative. The 585 nm flash-lamp-pumped pulsed dye laser is the most commonly reported laser used in treatment of SD. Other light and laser modalities such as intense pulsed light, radiofrequency, non-ablative, and ablative fractional lasers show a positive efficacy result as the single modality. However, none of these single modalities is sufficiently effective. Several trials have attempted treatment of striae alba by combined therapy. Suh DH et al.<sup>6</sup> reported that striae were treated by RF and 585 nm pulsed dye laser. However, they treated individuals with combined therapy at the first treatment. Shin JU et al.<sup>7</sup> reported that striae were treated with succinylated atelocollagen and ablative fractional laser. However, while an ablative fractional resurfacing laser is effective, the effect of succinylated atelocollagen was not proven.

Fractional photothermolysis reported an increase in the number of collagen and elastin fibers.<sup>8</sup> The use of radiofrequency devices have been

reported to be an effective and safe noninvasive technique to tighten the skin. It is reported that collagen fibril contraction occurs immediately after RF treatments, which induces new collagen formation.<sup>9</sup> We used PRP for transepidermal delivery materials. Platelet-granules have been shown to contain mitogenic and chemotactic growth factors important in wound healing such as PDGF, TGF-, VEGF, EGF, and IGF. PRP is known to accelerate proliferation of human skin fibroblasts and increase type I collagen expression.<sup>10</sup> Combined therapy of ablative fractional laser and PRP induced rapid healing after ablative resurfacing; a decreased erythema index and melanin index have also been reported. In this study, considering the darker skin of the Asian patients, plasma fractional radiofrequency and PRP treatment using ultrasound treatment were expected to function synergistically with fewer side effects.

Histologically, in the early stage of striae distensae, there are dermal edema and perivascular lymphocytic cuffing,<sup>11</sup> and, in the later stage, atrophy and loss of rete ridges occur.<sup>12</sup> There is loss of the normal random collagen distribution to the level of the mid dermis or deeper. Elastin stains reveal scarce or absent elastin fibers and reduced fibrillin in the papillary and reticular dermis within affected areas; the elastin fibers present appear tangled and frayed.<sup>12</sup> Waton RE et al.<sup>12</sup> have demonstrated that striae are associated with a loss of fibrillin and that improvement in the clinical appearance of striae after treatment with retinoic acid correlates with new fibrillin production. Enrique et al.<sup>12</sup> reported that epidermal and dermal thickness increased after IPL treatment in 2002. In this study, histological sections showed the increase of both collagen and elastic fibers was found in the papillary and reticular dermis as well as in subepidermal basal zones. It was suggested that those histological changes might improve the striae distensae in clinically.

We observed that the plasma fractional radiofrequency and transepidermal delivery using ultrasound therapy required a shorter period of time (two months) for favorable results. Algorithms for treatment will most likely be optimized in the future. Fractional ablative radiofrequency and transepidermal delivery using ultrasound is useful in the treatment of striae distensae.

**Conflict of interest: None**

## REFERENCES

1. Nouri K, Romagosa R, Chartier T, et al. Comparison of the 585-nm Pulsed Dye Laser and the Short Pulsed CO<sub>2</sub> Laser in the Treatment of Striae Distensae in Skin Types IV and VI. *Dermatol Surg.* 1999;25:368-370
2. Jimenez GP, Flores F, Berman B, et al. Treatment of striae rubra and striae alba with the 585-nm pulsed dye laser. *Dermatol Surg.* 2003;29:362-365

3. Barry LE, Jennifer EW, Joel H. Platelet Quantification and Growth Factor Analysis from Platelet-Rich Plasma: Implications for Wound Healing. *Plast Reconstr Surg* 2004;114:1502-1508
4. Na JI, Choi JW, Choi HR, et al. Rapid healing and reduced erythema after ablative fractional carbon dioxide laser resurfacing combined with the application of autologous platelet-rich plasma. *Dermatol Surg*. 2011;37:463-468
5. Lee JW, Kim BJ, Kim MN, et al. The efficacy of autologous platelet rich plasma combined with ablative carbon dioxide fractional resurfacing for acne scars: a simultaneous split-face trial. *Dermatol Surg*. 2011;37:931-938
6. Suh DH, Chang KY, Son HC, et al. Radiofrequency and 585-nm pulsed dye laser treatment of striae distensae: a report of 37 Asian patients. *Dermatol Surg*. 2007;33:29-34
7. Shin JU, Roh MR, Rah DK, et al. The effect of succinylated atelocollagen and ablative fractional resurfacing laser on striae distensae. *J Dermatolog Treat*. 2011;22:113-121
8. Kim BJ, Lee DH, Kim MN, et al. Fractional photothermolysis for the treatment of striae distensae in Asian skin. *Am J Clin Dermatol*. 2008;9:33-37
9. Zelickson BD, Kist D, Bernstein E, et al. Histological and ultrastructural evaluation of the effects of a radiofrequency-based nonablative dermal remodeling device: a pilot study. *Arch Dermatol*. 2004;140:204-209
10. Cho JW, Kim SA, Lee KS. Platelet-rich plasma induces increased expression of G1 cell cycle regulators, type I collagen, and matrix metalloproteinase-1 in human skin fibroblasts. *Int J Mol Med*. 2012;29:32-36
11. Burrows NP, Lovell CR. Disorders of connective tissue. In: Burns T, Breathnach S, Cox N, Griffiths C, eds. *Rook's textbook of dermatology*. 7th ed. Malden, MA: Blackwell Science. 2004:46.6
12. Watson RE, Parry EJ, Humphries JD, et al. Fibrillin microfibrils are reduced in skin exhibiting striae distensae. *Br J Dermatol*. 1998;138:931-937
13. Hernández-Pérez E, Colombo-Charrier E, Valencia-Ibieta E. Intense pulsed light in the treatment of striae distensae. *Dermatol Surg*. 2002;28:1124-1130

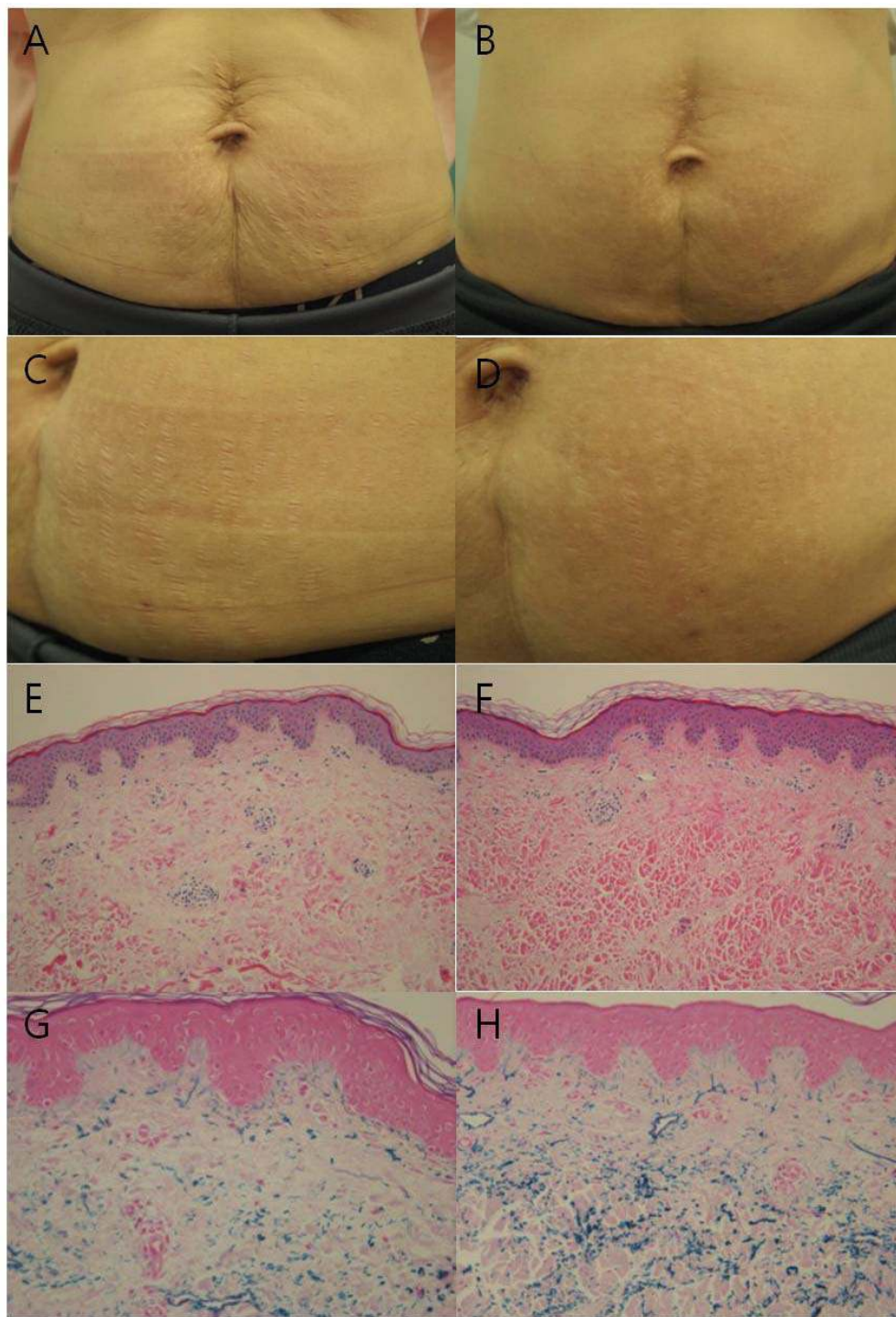
## Figure legends

### Figure 1

Improvement of striae distensae is noted in the abdominal skin, compared with before treatment (A)(C), and 2 months after the final combination treatment (B)(D). Histology of abdominal skin before treatment, showing decreased both collagen fibers in reticular dermis by H&E staining (x 200) (E), and elastic fibers by Victoria blue staining (x 200) (G). Histology of abdominal skin after the final combination treatment, showing increased both collagen fibers in reticular dermis by H&E staining (x 200) (F), and elastic fibers by Victoria blue staining (x 200) (G).

JUST ACCEPTED





## Figure 2

Improvement of striae distensae is noted in the abdominal skin, compared with before treatment (A), and 2 months after the final combination treatment (B). Histology of abdominal skin before treatment, showing slightly decreased both collagen fibers upper reticular dermis by H&E staining (x 200) (C), and elastic fibers by Victoria blue staining (x 200) (E). Histology of abdominal skin after the final combination treatment, showing slightly increased both collagen fibers by H&E staining (x 200) (D), and elastic fibers by Victoria blue staining (x 200) (F).

